

See discussions, stats, and author profiles for this publication at: <https://www.researchgate.net/publication/301270733>

Novel Surgical Technique for Discogenic Cauda Equina Syndrome – Transforaminal Intra Discal Access by Annulotomy outside Central Spinal Canal

Article · January 2016

DOI: 10.4172/2165-7939.S7-008

CITATION

1

READS

19

1 author:



[Sreedharan Namboothiri](#)

Kovai Medical Center and Hospital

9 PUBLICATIONS 14 CITATIONS

[SEE PROFILE](#)

Some of the authors of this publication are also working on these related projects:



for Endoscopy lecture [View project](#)

Novel Surgical Technique for Discogenic Cauda Equina Syndrome - Transforaminal Intra Discal Access by Annulotomy outside Central Spinal Canal

Sreedharan Namboothiri PE^{1*}, Satishchandra Gore² and Poorana Raja³

¹Consultant Orthopaedic Spine Surgeon and Director of Spine Fellowships, Kovai Medical Centre and Hospitals, Coimbatore, Tamil Nadu, 641014, India

²Spine endoscopic surgeon Pune India

³Spine Fellow, Kovai Medical Centre and Hospitals, Coimbatore, Tamil Nadu, 641014, India

Introduction

Cauda equina syndrome is characterised by disturbed function of multiple sacral and lumbar nerve roots in the lumbar vertebral canal resulting in impairment of bladder, bowel, or sexual function. Since the sacral roots are more at midline in lumbar dural sac a central disc herniation of large size can be a cause. The large central herniation causing cauda equina syndrome stretches the roots. Best results are obtained by decompression.

The cauda is draped over the disc and compressed between disc and lamina. The placement of an instrument with large footplate like standard spinal punches under the lamina during laminectomy may further compress and damage neural tissue in posterior access. This can be avoided by better surgical technique (e.g. the use of a high-speed drill instead of a Kerrison rongeur in patients with severe spinal stenosis) [1]. The decompression needs to be adequate enough to allow access lateral to the cauda and enough to retrieve the fragments.

There are differing opinions about surgical technique. Conventionally open procedures of wide bilateral laminectomy with medial facetectomy, extensive decompression with foraminotomies if needed for stenosis and a lateral annulotomy and discectomy have been employed for the treatment of discogenic cauda equina syndrome [2]. Aggressive removal of disc material in decompression is also advised. A laminotomy/hemi laminectomy with micro-discectomy is thought but not recommended as undue traction might be placed on the thecal sac and nerve roots during decompression, potentially worsening neurologic injury. In literature a transdural (intradural) access is reported, to reduce traction injury to nerve roots, when decompressing calcified central herniations. There are no published reports of comparison studies of the outcomes of these different access techniques [2].

The approach in any surgery depends on the pathoanatomy. With superfine imaging in MRI it is possible to appreciate a dural sac compromise and the involvement of nerve roots and changed blood supply and the pathoanatomy of cauda equina syndrome caused by a large fragment. This may cause enhancement on a MRI image with gadolinium [3]. We are able to appreciate the intra discal changes due to the outward movement of the fragment thru the annular tear. Newer minimally invasive transforaminal techniques to reduce morbidity and handling of neural tissue and to facilitate early rehabilitation and return to work are now possible.

We report here two cases of percutaneous transforaminal endoscopic access for inside out lumbar discectomy done under local anaesthesia for acute cauda equina syndrome caused by herniated intervertebral disc at L4-L5 level. One patient had associated canal stenosis. This is mainly to highlight the ease of access and patient outcomes, with pre and post images to support our report.

Case Report

Case 1

A 22-year-old male presented with history of low back pain of one-month duration with radiating pain to right lower limb. On physical

examination, straight leg raising test (SLRT) on right side was 25 degrees with normal SLRT on left side. Further manual muscle testing showed Extensor hallucis longus weakness on right side. There was sensory disturbance in the form of hypoesthesia and numbness along the L5 dermatomal level. He underwent an MRI scan (Figures 1A and B) and a diagnosis of L4-L5 disc prolapse with L5 radiculopathy was made. He was counselled on various treatment options available. He worsened during one week; time taken by patient to opt for surgery. He was taken up as emergency surgery

He presented with worsening pain in lower back and both lower limbs. Examination showed worsened neurological status with SLRT of 20 degrees on right side and 40 degrees on left side with both Tibialis anterior and Extensor hallucis longus (EHL) muscle weakness on right side with a power of 3/5 on manual muscle testing. Paraesthesia and numbness in perianal area was also present with decreased sphincter tone. A diagnosis of early cauda equina syndrome was confirmed and he was posted for Percutaneous Endoscopic decompression by transforaminal access.

Surgical technique: Optimum location for skin entry and guide wire insertion was assessed preoperatively using a limited plain axial CT scan at the L4-5 level (Figure 2). The CT scan helped plan trajectory clear of bowel and retroperitoneal structures like kidney. If we draw a sub facet line in this view it clearly shows us presence of disc tissue

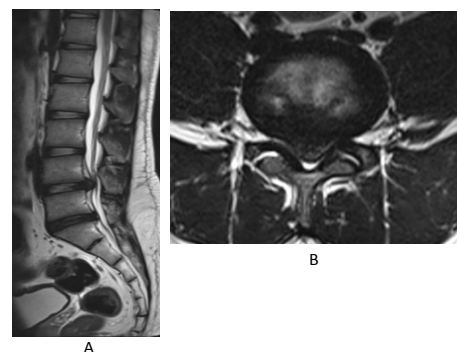


Figure 1: Pre op sagittal and axial MRI pictures showing a large central disc at L4-5 level causing severe stenosis of the neural canal and severely compressed thecal sac.

***Corresponding author:** Sreedharan Namboothiri PE, Consultant Orthopaedic Spine Surgeon and Director of Spine Fellowships, Kovai Medical Centre and Hospitals, Coimbatore, Tamil Nadu, 641014, India, Tel: 0422 432 3800; E-mail: sreedharannamboothiri@gmail.com

Received February 15, 2016; **Accepted** March 08, 2016; **Published** March 10, 2016

Citation: Namboothiri S, Gore S, Raja P (2016) Novel Surgical Technique for Discogenic Cauda Equina Syndrome - Transforaminal Intra Discal Access by Annulotomy outside Central Spinal Canal. J Spine S7: 008.doi:10.4172/2165-7939.S7-008

Copyright: © 2016 Namboothiri S, et al. This is an open-access article distributed under the terms of the Creative Commons Attribution License, which permits unrestricted use, distribution, and reproduction in any medium, provided the original author and source are credited.

dorsal to this line indicating a severe compromise of the canal and neural structures. It is also very important to note that the posterior border of the disc which is normally concave is turned convex due to the herniation.

Patient was positioned prone. After proper draping, reference skin lines were drawn under C-arm guidance for skin entry. The local anaesthetic agent (0.5% lignocaine) infiltrated along the track up to foramen. Intravenous sedation (with Midazolam and Fentanyl) was used but patient can obey and communicate freely with the surgeon throughout the procedure. This was significant in this case as we were putting an instrument in canal through foramen and likely to increase pressure over the dural sac. Antero posterior and lateral fluoroscopic images were used and a Vertebri 8 mm (Richard Wolf, Germany) endoscopic system employed.

Safe entry into L4-L5 disc space reached through the foramen biportally. Needle was inserted under posterior annulus conceptually under the line touching both subfacet areas. (as seen in section above).

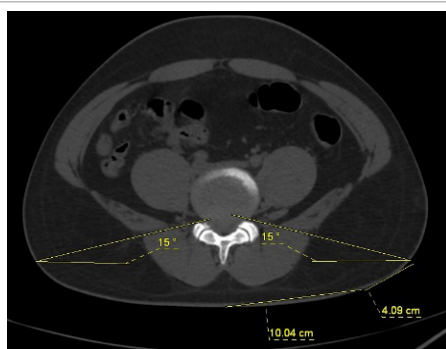


Figure 2: Pre op CT scan - optimum position for guide pin insertion found out using pre op axial CT scan and found to be upto but < 14 cm from midline.

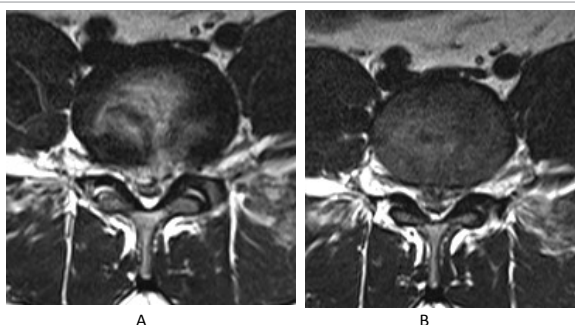


Figure 3: Post op MRI- T2 axial pictures at L4-5 showing decompressed thecal sac with some residual disc and small post-operative hematoma.

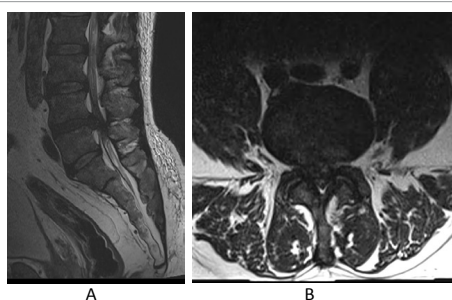


Figure 4: Pre op sagittal and axial MRI images showing a large central L4-L5 disc with severe cauda equina compression.

A guide wire was inserted into the disc space through a puncture wound followed by the insertion of obturator and cannula first on more symptomatic side. Patient feedback as to increased pain or discomfort or neurological complaints was noted. After cannula insertion, the obturator removed and the endoscope was introduced. The central annular tear was identified. Additional intra discal part of the nucleus was removed to create more working space and then herniated disc material removed. After decompressing the thecal sac and nerve root from right side, same technique was used from the left side and herniated disc material was cleared. Adequate decompression was evident from the pulsation of the dural sac and mobile nerve roots intra-operatively and immediate post-operative pain relief as reported by the patient. His SLRT improved in the immediate post- operative period with resolution of symptoms like perianal and saddle anaesthesia was seen in short time.

Physical examination in the immediate post-operative period showed improvement in motor power in right lower limb with SLRT of 90 degrees on both sides. Repeat MRI in the immediate post-operative period (Figures 3A and 3B) showed decompressed spinal canal and foramina but some residual disc material and a small postoperative hematoma in the L4-L5 disc space. This is known to resolve with time and was managed by wait and watch policy. Patient was discharged on the same day and he resumed his table work within a week. He was under regular follow up and his recent visit 9 months after the procedure showed complete resolution of clinical symptoms and signs.

Case 2

A 60-year-old male presented with low back pain of 6 months' duration with neurogenic claudication. Clinical examination showed bilateral SLRT being positive with no deficit.

An MRI scan done and he was diagnosed as having L4-L5 disc prolapse with spinal canal narrowing. He was advised decompression surgery. He was counselled about the options. Decision to undergo surgery was taken by patient after about 6 months a total 12 months after the origin of symptoms; when he presented to us with severe back pain and lower limb pain with bladder and bowel incontinence. Physical examination showed bilateral positive SLRT with bilateral lower limb L5 and S1 weakness. He had altered perianal sensation with decreased rectal tone. A diagnosis of acute discogenic cauda equina syndrome due to L4-L5 disc prolapse with lumbar canal stenosis was made and he was taken up for emergency surgery.

A percutaneous endoscopic lumbar discectomy was done and clearance of the prolapsed disc material done under local anaesthesia. A repeat post op MRI (Figures 5A and 5B) showed decompressed spinal canal with residual disc material to left side.

It was decided to go for repeat procedure from left side and further clearance of the residual disc material done. In the post procedure MRI (Figures 6A and 6B) there is annular shell but during surgery a pulsatile dural sac was appreciated.

Following the biportal procedure patient improved rapidly with resolution of his preoperative symptoms. Bowel and bladder control started improving following the procedure. Final follow up after one year showed complete resolution of pre-operative symptoms.

Discussion

In case one a biportal access helped us clear the compression. The irrigation used during scopy may have helped in washing away and clear away chemical irritation. In case two our initial one sided access was not adequate to decompress the neural tissue lesion sufficiently as seen

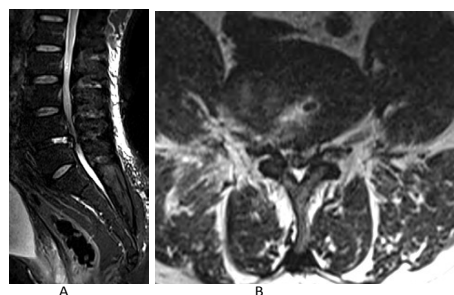


Figure 5: First surgery postoperative MRI done following initial procedure showing decompressed canal with residual disc.

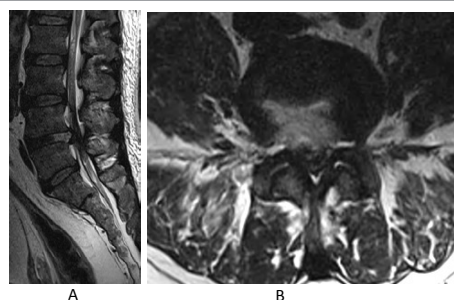


Figure 6: Second surgery post-operative MRI repeated after the final procedure showing well decompressed spinal canal.

from the images in first surgery post op images. Patient had continued symptoms and signs which with biportal access resolved. The images second surgery post op shows the adequacy of the decompression.

Though percutaneous endoscopic spine surgery was used initially only for contained disc herniations, the indications are being rapidly getting expanded, as more surgeons get trained. The technique can address extruded and migrated discs, large discs occupying more than 50% of the spinal canal, spinal canal stenosis and disc space infection/discitis. L5/S1 disc prolapse with high iliac crest is a relative contraindication.

This report is about application of inside out technique of transforaminal percutaneous access to disc and removal of fragment by a lateral annular window. These highlight the utility of transforaminal approach with an annulotomy outside the spinal canal in the safe delivery of the disc fragment in presence of a tightly compressed thecal sac. Introduction of instruments into the disc space is known to increase the intra discal pressure but of no significance as patient is awake and aware increasing safety and likely changes in neural function are detected immediately.

In inside out technique has been popularized by Yeung and Gore [4] Percutaneous trans foraminal endoscopic access for discectomy is thru lateral annular window, the landing is thru kamin's triangle into the empty space left behind intra discally by the outgoing fragment. The annulotomy is essentially made in the foraminal area which is away from the compressed cauda equina fibers and hence has no risk of worsening the neurological deficit. It should also be noted that herniation has already deflated the disc and as we come from the sides it is very unlikely to involve handling of the neural tissue. If necessary, the annulotomy can be easily extended medially without any effect on the dural sac. Herniated fragment displaces the thecal sac dorsally (as seen with line joining sub facet surfaces in cross section MRI) away from instrument track making shallow transforaminal approach easier.

Kamin and Gellman introduced the percutaneous arthroscopic

posterolateral extracanal approach for treating disc herniation. This later evolved into inside out approach popularised by Yeung and Gore [4]. This posterolateral endoscopic technique is less invasive than the standard posterior approach microdiscectomy. To ensure the safety of the neural structures, real time conscious patient interaction during the procedure is very helpful. Owing to its low level of invasiveness, postoperative back pain is minimal and patients generally enjoy faster functional recovery

Advantage of transforaminal inside out technique under local anaesthesia is its minimising iatrogenic nerve root injury and also risk of conventional anaesthetic techniques. Incision is 8mm, so an advantage of better aesthetic outcome. As it is evident from the present report it can be performed as an emergency procedure. Pre op considerations differ from conventional open surgery as we can manage medical co morbidity well under local anaesthesia.

The skin entry is in posterolateral aspect of the lower back (approximately 8-14 cm from the midline) and it was approximately 14 cm in the presented cases. It proceeds through the Kamin's triangle, which is bordered superolaterally by exiting nerve root, posteriorly by the superior articular process of facet joint and caudally by the inferior pedicle, medially lies the dural sac and the traversing root. The location of the skin entry point is critical for passing the endoscope underneath the facet joint and reaching the disc hernia site. In patients with large body sizes, the ideal skin entry point is more laterally located than those with small body sizes. In addition, to reach posteriorly and medially enough to get the centrally located or migrating disc, the location of the skin entry point should be more lateral. Our ability to target the fragment without causing more collateral damage is best in this approach. Bringing the fragment in line of our vision may require removal of bone in the foraminal walls at times. Alternatively, use of a hook or flexible graspers helps to achieve a complete removal of the fragment without additional bone cutting [5-10].

Microdiscectomy or open posterior transcanal approach makes paraspinal muscle stripping, as well as lamina, facet joint, ligamentum flavum excision and nerve root manipulation inevitable. Open surgery resulted in more soft tissue violation and even bony resection which increases the risk of post-operative instability and eventually increases the rate of spinal fusion. In one study, the incidence of post decompression spondylolisthesis has been reported to range from 2 to 10%. Furthermore, during open procedures, nerve root has to be retracted medially, which increases the possibility of Neuro deficit. True realistic reporting of neurological worsening after a surgery for cauda equina syndrome is lacking [11-15].

Conclusion

It is better to approach the disc fragment in discogenic cauda equina syndrome through a foraminal annulotomy, as in inside out variety of percutaneous endoscopic lumbar discectomy. Concept of using a sub facet line in cross section images in MRI to confirm the indication of transforaminal access in cauda equina syndrome due to disc herniation is also proposed. The structures lying ventral to this line if include disc material due to central annular tear and herniation we must take a transforaminal access. We feel a transforaminal access may affect outcome of surgery positively, but number is too small we need further acceptance of the technique by large number of surgeons to validate our point. We suggest a healthy discussion on the non-invasive technique of surgery. Most literature on surgery for cauda equina surgery has been on timing of surgery and not much on technique of retrieving the fragment without causing neural handling [16].

References

1. Fehlings MG, Zeidman SM, Jha N, Rampersaud YR (2012) Spine surgery- Techniques, Complication avoidance and management. In: Benzel EC (ed.) Cauda equina syndrome. (3rd edn), Elsevier Saunders.
2. Gitelman A, Hishmeh S, Morelli BN, Joseph SA Jr, Casden A, et al. (2008) Cauda equina syndrome: a comprehensive review. Am J Orthop (Belle Mead NJ) 37: 556-562.
3. Kobayashi S, Uchida K, Takeno K, Baba H, Suzuki Y, et al. (2006) Imaging of cauda equina edema in lumbar canal stenosis by using Gadolinium-enhanced MR Imaging: Experimental constriction injury. AJNR Am J Neuroradiol 27: 346-353.
4. Gore S, Yeung A (2014) The "inside out" transforaminal technique to treat lumbar spinal pain in an awake and aware patient under local anesthesia: results and a review of the literature. Int J Spine Surg 1: 8.
5. Jha SC, Tonogai I, Takata Y, Sakai T, Higashino K, et al. (2015) Percutaneous endoscopic lumbar discectomy for a huge herniated disc causing acute Cauda equina syndrome: A case report. J Med Invest 6: 100-102.
6. Tzaan WC (2007) Transforaminal percutaneous endoscopic lumbar discectomy. Chang Gung Med J 30: 226-234.
7. Postacchini F, Postacchini R (2011) Operative management of lumbar disc herniation: the evolution of knowledge and surgical techniques in the last century. Acta Neurochir Suppl 108: 17-21.
8. Ahn Y, Lee SH, Park WM (2004) Percutaneous endoscopic lumbar discectomy for recurrent disc herniation- surgical technique, outcome, prognostic factors for 43 consecutive cases. Spine (Phila Pa 1976) 15: E326-E332.
9. Lee S, Kim SK, Lee SH, Kim WJ, Choi WC, et al. (2007) Percutaneous endoscopic lumbar discectomy for migrated disc herniation: classification of disc migration and surgical approaches. Eur Spine J 16: 431-437.
10. Yeung AT, Tsou PM (2002) Posterolateral endoscopic excision for lumbar disc herniation: surgical technique, outcome and complications in 307 consecutive cases. Spine 27: 722-731.
11. Shapiro S (1993) Cauda equina syndrome secondary to lumbar disc herniation. Neurosurgery 32: 743-746.
12. Kostuik JP, Harrington I, Alexander D, Rand W, Evans D (1986) Cauda equina syndrome and lumbar disc herniation. J Bone Joint Surg Am 68: 386-391.
13. Hussain SA, Gullan RW, Chitnavis BP (2003) Cauda equina syndrome: outcome and implications for management. Br J Neurosurg 17: 164-167.
14. Dinning TA, Schaeffer HR (1993) Discogenic compression of the cauda equina: a surgical emergency. Aust N Z J Surg 63: 927-934.
15. Schaeffer HR (1966) Cauda equina compression resulting from massive lumbar disc extrusion. Aust N Z J Surg 35: 300-306.
16. Podnar S (2010) Cauda equina lesions as a complication of spinal surgery. Eur Spine J 19: 451-457.

Citation: Namboothiri S, Gore S, Raja P (2016) Novel Surgical Technique for Discogenic Cauda Equina Syndrome - Transforaminal Intra Discal Access by Annulotomy outside Central Spinal Canal. J Spine S7: 008.doi:[10.4172/2165-7939.S7-008](https://doi.org/10.4172/2165-7939.S7-008)

This article was originally published in a special issue, [Spinal Cord Injury Rehabilitation](#) handled by Editor(s). Dr. Alessandro Landi, University of Rome, Italy

Submit your next manuscript and get advantages of OMICS Group submissions

Unique features:

- Increased global visibility of articles through worldwide distribution and indexing
- Showcasing recent research output in a timely and updated manner
- Special issues on the current trends of scientific research

Special features:

- 700 Open Access Journals
- 50,000 editorial team
- Rapid review process
- Quality and quick editorial, review and publication processing
- Indexing at PubMed (partial), Scopus, DOAJ, EBSCO, Index Copernicus and Google Scholar etc
- Sharing Option: Social Networking Enabled
- Authors, Reviewers and Editors rewarded with online Scientific Credits
- Better discount for your subsequent articles

Submit your manuscript at: <http://www.omicsonline.org/submission>